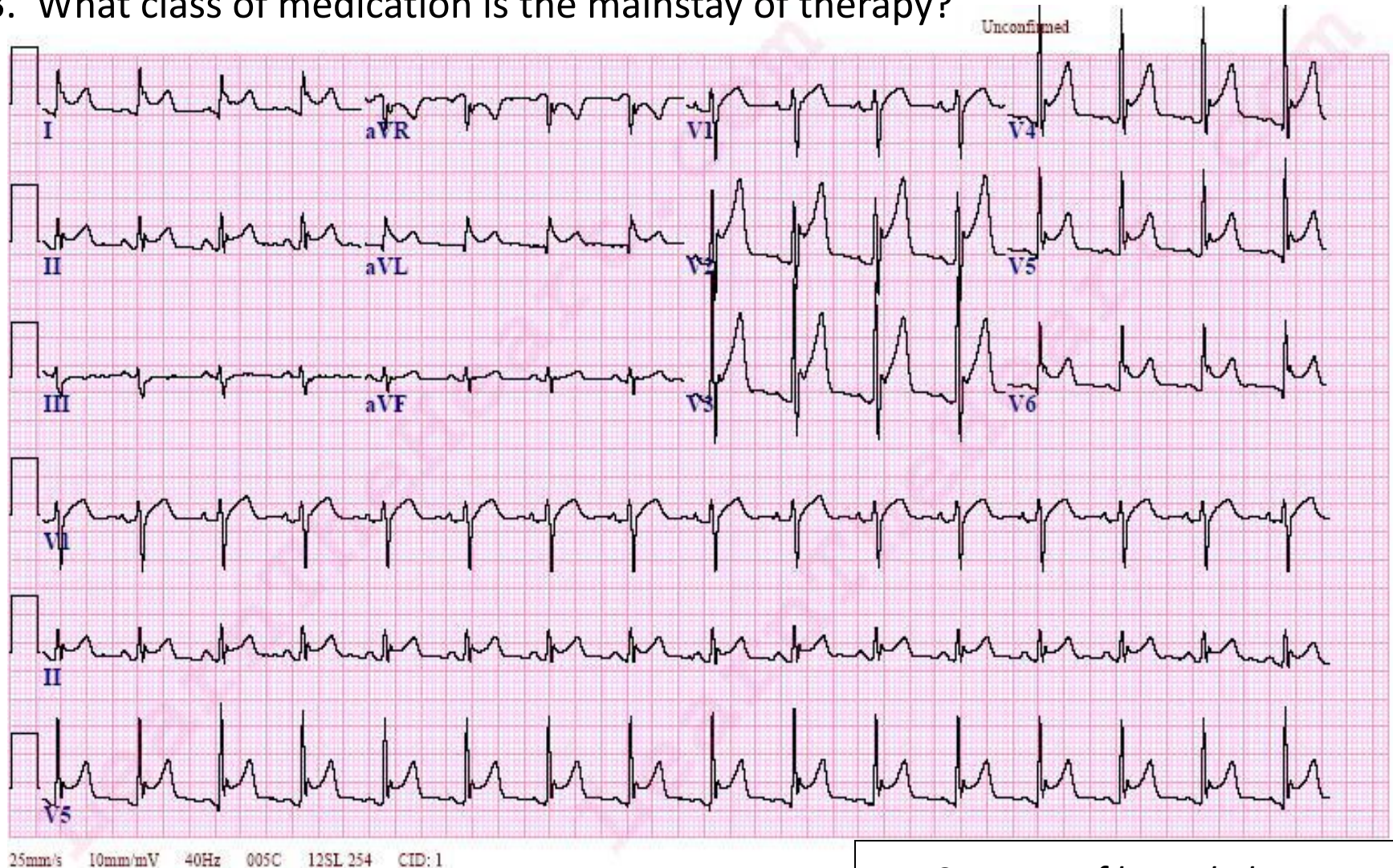


This is a 16 year old male with a history of chest pain for 2 days.

1. What is the rate, rhythm, and axis?
2. What is the most likely diagnosis?
3. What class of medication is the mainstay of therapy?



Answers to ECG of the week

1. What is the rate, rhythm, and axis?

Rate is about 96bpm. Rhythm appears to be normal sinus. Axis is somewhere around 0 to -10 degrees or so, which in a 16 year old is a borderline left axis deviation.

2. What is the most likely diagnosis?

Pericarditis. Note the significant ST- elevation across all of the precordial leads. Other findings include PR depression in lead II and sinus tachycardia.

3. What class of medication is the mainstay of therapy?

Nonsteroidal anti-inflammatories are the hallmark of treatment in Pericarditis. Other modalities of treatment include pericardiocentesis when there is concern for the development of cardiac tamponade and colchicine has been used as an adjunct to NSAIDs. Colchicine has been noted to reduce recurrence rates and improve symptom relief in 72 hours.