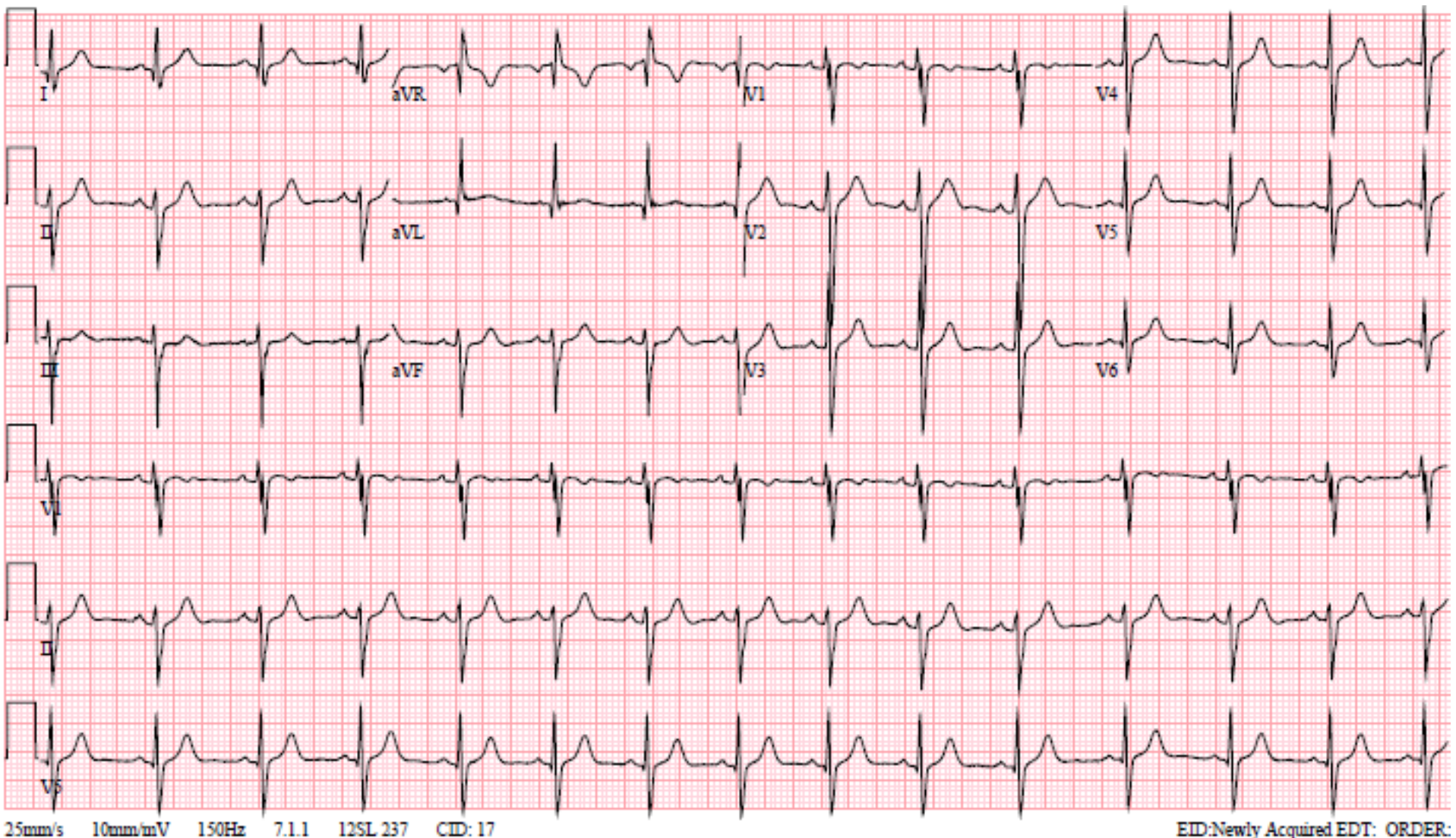


A 16 year old boy comes to the pediatrician's office for a pre-athletic screening visit (true story). You obtain the ECG seen below.

1) What is the major abnormality on this ECG? (1point)

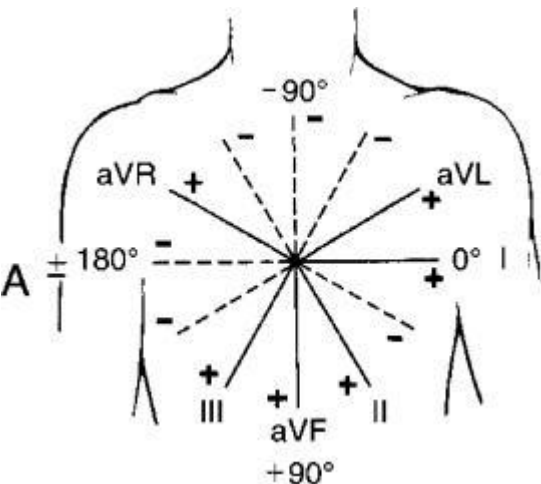
2) Name 2 structural, congenital heart problems that can result in this ECG pattern (1 point each).



1) What is the major abnormality on this ECG? (1point)

The major abnormality is a left axis deviation. This refers specifically to the QRS complex. In the typical teenager, the QRS is usually directed downward and to the left. A left axis deviation means the QRS vector is directed even further to the left than we would expect.

Let's review how to check axis. The easiest way is to look at leads I and lead aVF:



Electric vectors moving toward a lead cause a positive deflection on an ECG, and vectors moving away from a lead cause a negative deflection. Lead I sits directly toward patient's left (0 degrees by convention). Lead aVF sits directly downward (90 degrees by convention).

In our patient, the QRS is upright in lead I (so it is leftward) and it is **downgoing** in lead aVF (so the QRS is directed **upward**). This is very abnormal and suggests either a major structural abnormality, or massive left ventricular hypertrophy.

2) Name 2 structural, congenital heart problems that can result in this ECG pattern (1 point each).

There are at least 2 congenital heart problems that yield this pattern of ECG. The first is tricuspid atresia. In tricuspid atresia, the RV is hypoplastic and thus the QRS direction is dominated by the LV forces, shifting it far to the left. The second congenital heart problem that can yield this pattern is an atrioventricular canal defect (AVC). The location of the ventricular septal defect in an AVC shifts the location of the His-Purkinje system downward, such that the ventricles depolarize from inferior to superior, flipping the QRS vector upward. In the diagram to the right, imagine the His-Purkinje system (in red) coursing along the inferior aspect of a ventricular septal defect that I've drawn in (in yellow).

