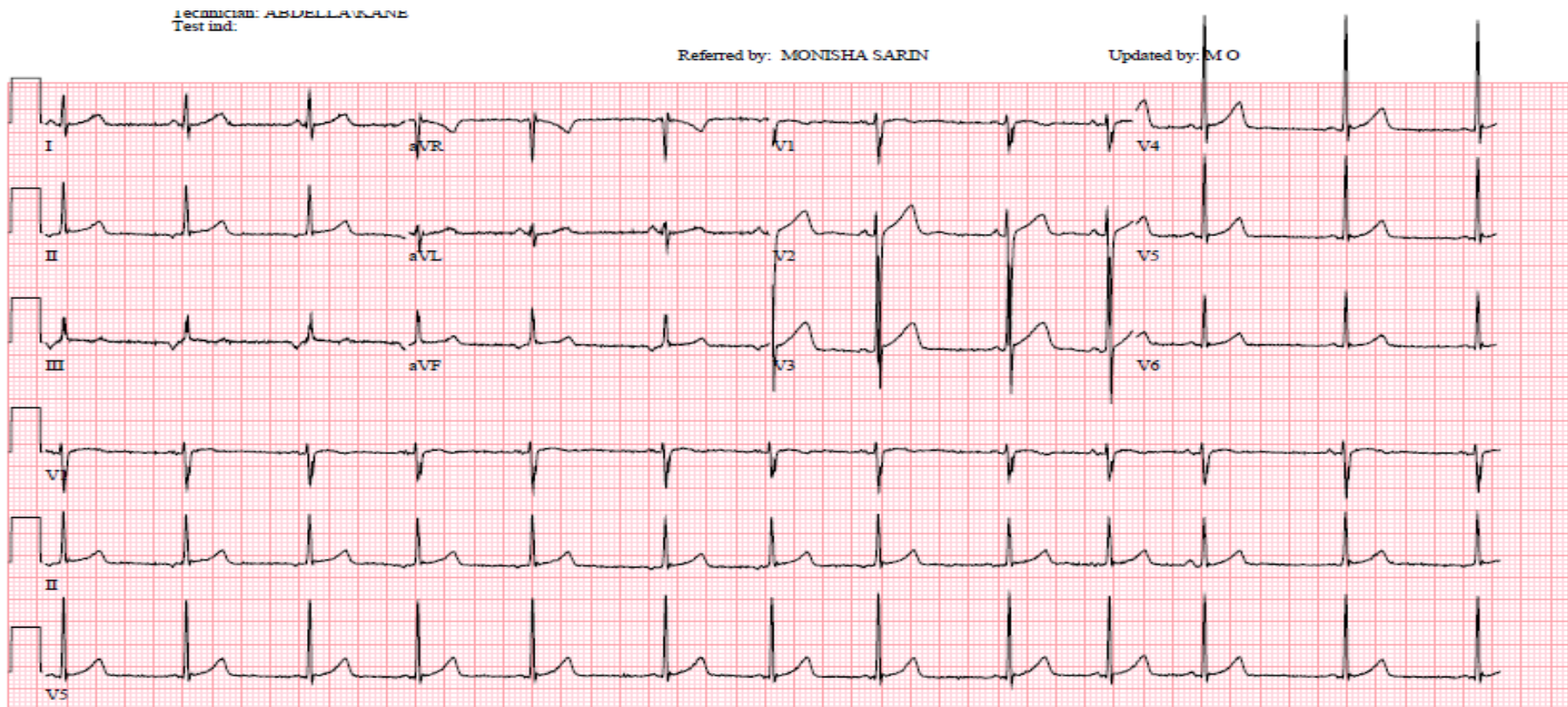


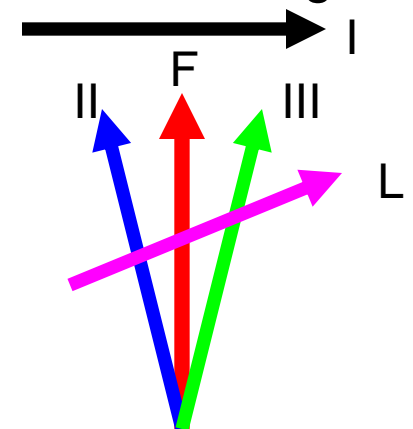
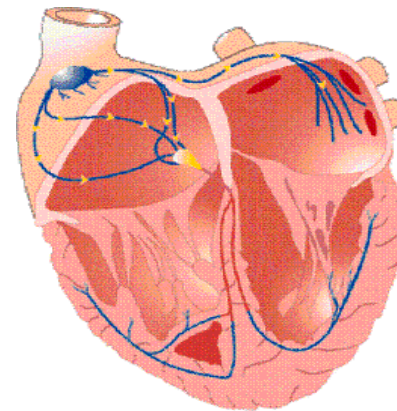
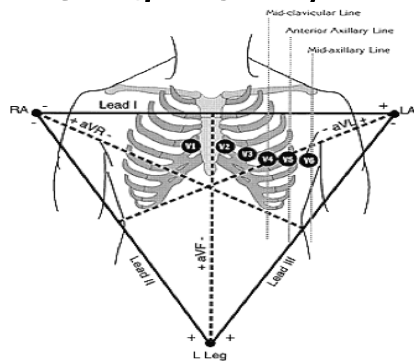
ECG of the week 8/23/2011

1. What is the rate (0.5 points) and is the p wave axis normal or abnormal (0.5 points)?
2. Where do you believe the atrial signal is being initiated from (high right atrium, low right atrium, high left atrium, low left atrium, left ventricle or right ventricle) – 1 point?
3. What arrhythmia involving this finding can produce a tachycardia induced cardiomyopathy (1 point)?



ECG of the Week Answers

1. Rate is ~ 70 bpm. The P wave axis is abnormal, so this is classified as an Ectopic Atrial Rhythm. It is a normal variant as long as the rate is within the normal range. Also note that the QRS morphology is normal due to the use of the His-Purkinje system to depolarize the ventricles.
2. Low right atrium. Note that the p waves are upright in I and **avL**, while they are inverted in leads **II**, **III**, **avF**, avR. This tells you that atrial depolarization is beginning inferiorly (**II**, **III**, **avF**) and spreading upwards (inverted p wave going away from the feet). Also, you know that the electrical impulse is beginning in the right atrium because the p wave is positive in I, **avL** (depolarization traveling towards the left arm) and negative in avR (depolarization heading away from the right arm).



ECG of the Week Answers

3. An ectopic atrial rhythm develops from enhanced automaticity of a group of atrial cells outside of the SA node. When these ectopic foci produce inappropriately rapid heart rates for prolonged periods of time as in ectopic atrial tachycardia (EAT), this can result in a tachycardia induced cardiomyopathy. All pediatric patients that present with cardiomyopathy or CHF should always have their p wave axes and morphology investigated, as treatment for EAT will result in improvement or resolution of their ventricular dysfunction.