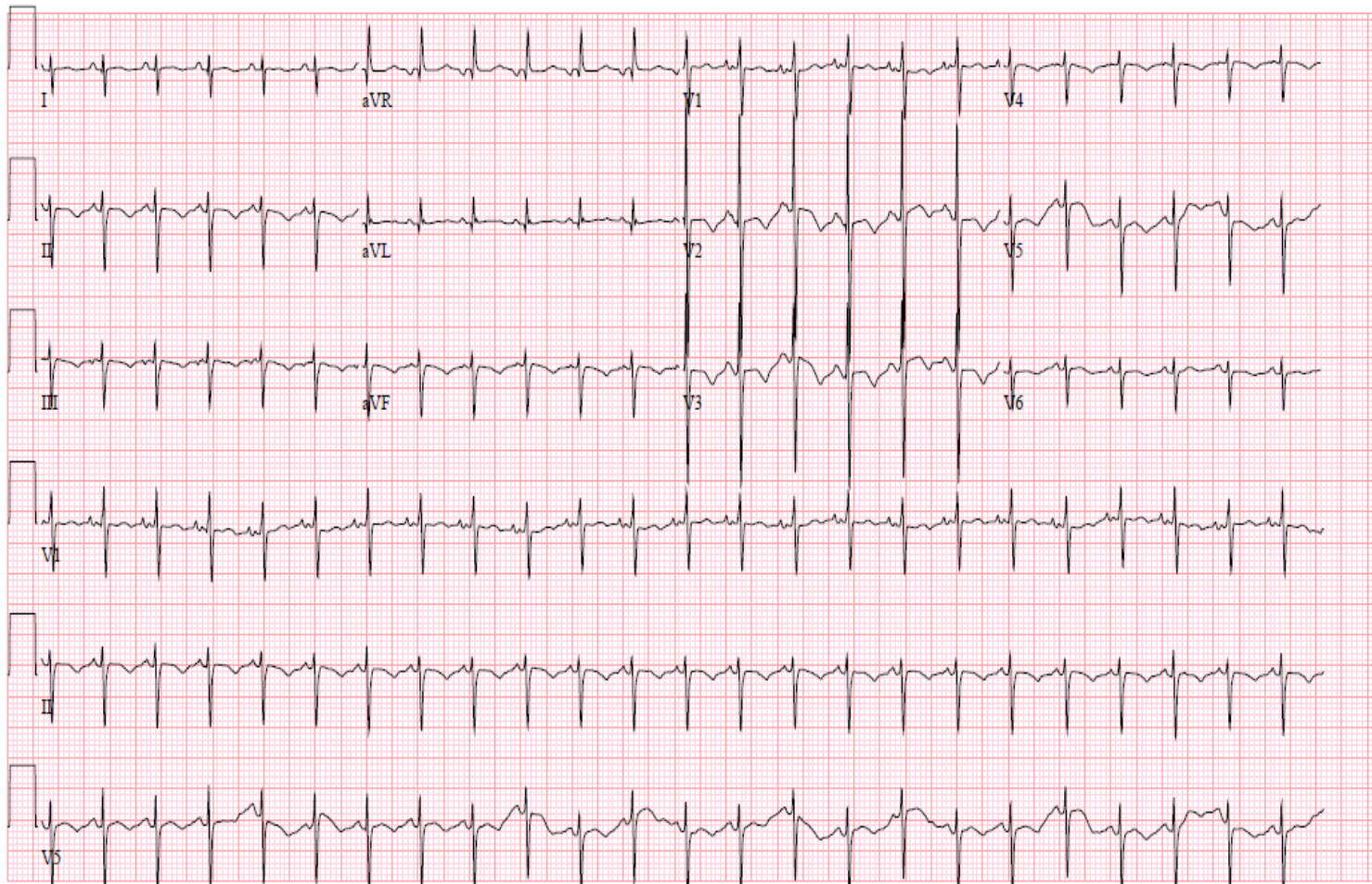


EKG of the Week Aug 23 2010

This EKG is from a 1-week-old male with Down syndrome seen for his initial evaluation. A heart murmur is present.

1. What is the rhythm and QRS axis? Is this normal?
2. What is the likely structural defect causing this problem?
3. When should we consider surgery to repair the defect (immediately, during infancy, or during school age)?



ANSWER FOR EKG of the Week

This EKG is from a 1-week-old male with Down syndrome seen for his initial evaluation. A heart murmur is present.

1. What is the rhythm and QRS axis? Is this normal?

There is sinus rhythm, with a “superior axis,” indicated by the primarily downward QRS in AVF, as well as the downward QRS in I. The QRS axis is therefore directed “Northwest” or upwards and to the left.

2. What is the likely structural defect causing this problem?

This child has a complete atrioventricular canal defect, which is the endocardial cushion defect commonly present in roughly one-third of children with Down syndrome (see figure). This defect results in an abnormal position of the A-V conduction tissue, resulting in the characteristic axis deviation.

3. When should we consider surgery to repair the defect (immediately, during infancy, or during school age)?

The defect results in severe pulmonary over-circulation, which can cause irreversible harm to the pulmonary vascular bed if not repaired by about 6 months of age in Down syndrome. However, the surgery is also technically complex, and requires an adequate sized heart after some growth from birth. Thus, the repair is usually performed between 3-4 months of age.

